

Wound, Ostomy and Continence Nurses Society's Guidance on OASIS-D Integumentary Items: Best Practice for Clinicians



Wound
Ostomy and
Continence
Nurses
Society®

Table of Contents

Table of Contents	2
Acknowledgments.....	3
Introduction.....	4
Purpose.....	4
Item Set	4
Pressure Injury Definition	5
Pressure Injury Classification System.....	5
Item Set Continued.....	9
Glossary	10
References.....	12
Acknowledgment about Content Validation.....	12

Acknowledgments

Wound, Ostomy and Continence Nurses Society's Guidance on OASIS-D Integumentary Items: Best Practice for Clinicians

This document was developed by the WOCN Society's OASIS Task Force between November 2018 – December 2018.

Task Force Chair:

Barbara Dale, BSN, RN, CWOCN, CHHN, COS-C,
Director of Wound Care
Quality Home Health
Livingston, Tennessee

Task Force Members:

Dianne Mackey, MSN, RN, CWOCN
Staff Educator
Kaiser Permanente Home Health, Hospice and Palliative Care
San Diego, California

Laurie McNichol, MSN, RN, CNS, GNP, CWOCN, CWON-AP, FAAN
Clinical Nurse Specialist/WOC Nurse
Cone Health
Greensboro, North Carolina

Ben Pierce, BA, RN, CWON
Vice President of Utilization and Quality Management
WoundTech
Hollywood, Florida

The Wound, Ostomy and Continence Nurses Society™ suggests the following format for bibliographic citations:

Wound, Ostomy and Continence Nurses Society. (2019). *Wound, Ostomy and Continence Nurses Society's guidance on OASIS-D integumentary items: Best practice for clinicians*. Mt. Laurel, NJ: Author.

Copyright © 2019 by the Wound, Ostomy and Continence Nurses Society. No part of this publication may be reproduced, photocopied, or republished in any form, in whole or in part, without written permission of the Wound, Ostomy and Continence Nurses Society.

Introduction

OASIS-D, scheduled for implementation on January 1, 2019, is a modification to the Outcome and Assessment Information Set (OASIS-C2) that Home Health Agencies must collect to participate in the Medicare program. OASIS-D includes modifications and new items to standardize care across post-acute care (PAC) settings pursuant to the provisions of the IMPACT Act (Centers for Medicare & Medicaid Services [CMS], 2018a).

Modifications in the OASIS-D integumentary status item set include removal of items:

- M1300 Pressure Ulcer Assessment
- M1302 Risk of Developing Pressure Ulcer
- M1313 Worsening of Pressure Ulcer Status
- M1320 Status of Most Problematic Pressure Ulcer
- M1350 Skin Lesion or Open Wound

Modifications to item text, intent or instructions were made to items (CMS, 2018b):

- M1306 Unhealed Pressure Ulcer/Injury at Stage 2 or Higher
- M1307 Oldest Stage 2 Pressure Ulcer
- M1311 Current Number of Pressure Ulcers/Injuries at Each Stage
- M1322 Current Number of Stage 1 Pressure Injuries
- M1324 Stage of Most Problematic Pressure Ulcer/Injury that is Stageable
- M1332 Current Number of Stasis Ulcer(s) that are Observable
- M1334 Status of Most Problematic Stasis Ulcer that is Observable
- M1340 Surgical Wound

Note: The terms, definitions, and illustrations describing pressure ulcer/injury stages in this document reflect the National Pressure Ulcer Advisory Panel’s (NPUAP) 2016 Pressure Injury Classification System and related illustrations. “When discrepancies exist between the NPUAP definitions and the OASIS scoring instructions provided in the OASIS guidance manual and CMS Q&A’s, providers should rely on the CMS OASIS instructions” (CMS, 2018c).

Purpose

The Wound, Ostomy and Continence Nurses Society (WOCN) developed the following guidelines to facilitate the classification of wounds by home health clinicians. This guidance document was developed by consensus among a panel of WOCN Society content experts. The document updates a previous document: Wound, Ostomy and Continence Nurses Society’s Guidance on OASIS-C2 Integumentary Items: Best Practice for Clinicians (WOCN, 2016). The original guidance document was developed in 2001 and has been previously updated in 2006, 2009, and 2016.

OASIS-D Integumentary Status (CMS, 2018d)

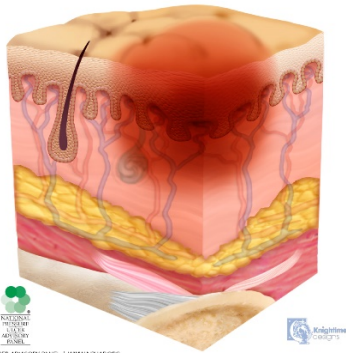
- **Item Set**
 - **(M1306) Does this patient have at least one Unhealed Pressure Ulcer/Injury at Stage 2 or Higher or designated as Unstageable?** (Excludes Stage 1 pressure injuries and all healed pressure ulcer/injuries)

- **Pressure Injury Definition** (NPUAP, 2016)

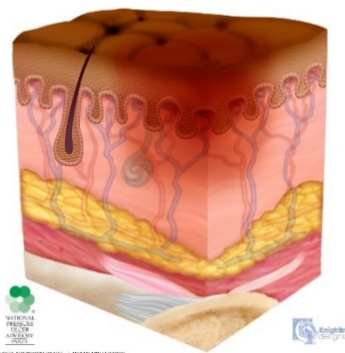
A pressure injury is localized damage to the skin and underlying soft tissue usually over a bony prominence or related to a medical or other device. The injury can present as intact skin or an open ulcer and may be painful. The injury occurs as a result of intense and/or prolonged pressure or pressure in combination with shear. The tolerance of soft tissue for pressure and shear may also be affected by microclimate, nutrition, perfusion, co-morbidities and condition of the soft tissue.

- **Pressure Injury Classification System** (NPUAP, 2016):

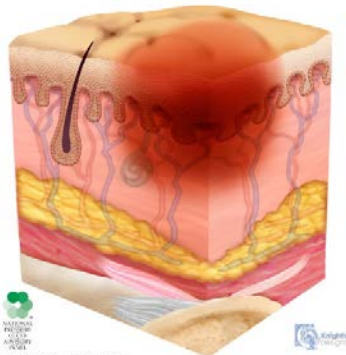
Stage 1 Pressure Injury - Lightly Pigmented



Stage 1 Pressure Injury – Darkly Pigmented



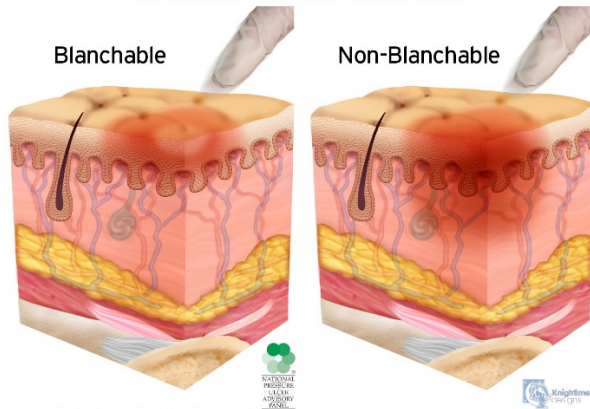
Stage 1 Pressure Injury – Edema



Blanchable vs Non-Blanchable

Blanchable

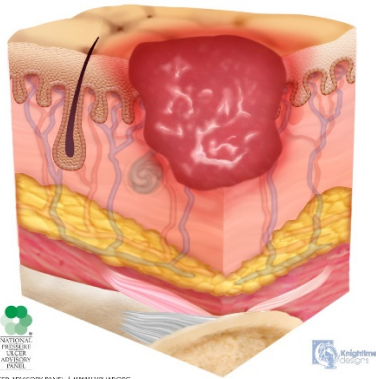
Non-Blanchable



Stage 1 Pressure Injury: Non-blanchable erythema of intact skin

Intact skin with a localized area of non-blanchable erythema, which may appear differently in darkly pigmented skin. Presence of blanchable erythema or changes in sensation, temperature, or firmness may precede visual changes. Color changes do not include purple or maroon discoloration; these may indicate deep tissue pressure injury.

Stage 2 Pressure Injury

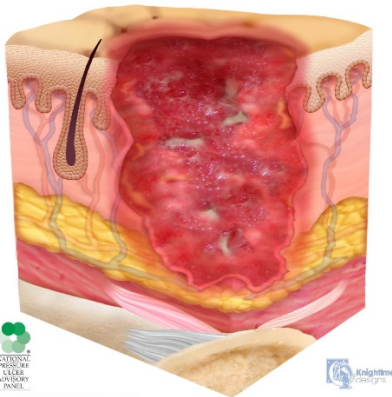


©2016 NATIONAL PRESSURE ULCER ADVISORY PANEL | WWW.NPUAP.ORG

Stage 2 Pressure Injury: Partial-thickness skin loss with exposed dermis

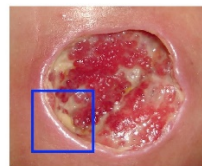Partial-thickness loss of skin with exposed dermis. The wound bed is viable, pink or red, moist, and may also present as an intact or ruptured serum-filled blister. Adipose (fat) is not visible and deeper tissues are not visible. Granulation tissue, slough and eschar are not present. These injuries commonly result from adverse microclimate and shear in the skin over the pelvis and shear in the heel. This stage should not be used to describe moisture associated skin damage (MASD) including incontinence associated dermatitis (IAD), intertriginous dermatitis (ITD), medical adhesive related skin injury (MARSI), or traumatic wounds (skin tears, burns, abrasions).

Stage 3 Pressure Injury

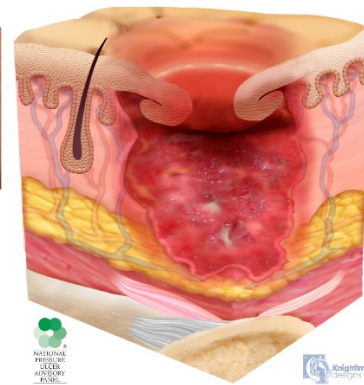


©2016 NATIONAL PRESSURE ULCER ADVISORY PANEL | WWW.NPUAP.ORG

Stage 3 Pressure Injury with Epibole



Area of Focus

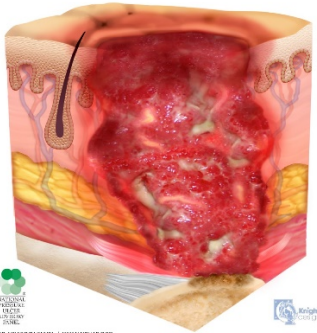


©2016 NATIONAL PRESSURE ULCER ADVISORY PANEL | WWW.NPUAP.ORG

Stage 3 Pressure Injury: Full-thickness skin loss

Full-thickness loss of skin, in which adipose (fat) is visible in the ulcer and granulation tissue and epibole (rolled wound edges) are often present. Slough and/or eschar may be visible. The depth of tissue damage varies by anatomical location; areas of significant adiposity can develop deep wounds. Undermining and tunneling may occur. Fascia, muscle, tendon, ligament, cartilage and/or bone are not exposed. If slough or eschar obscures the extent of tissue loss this is an Unstageable Pressure Injury.

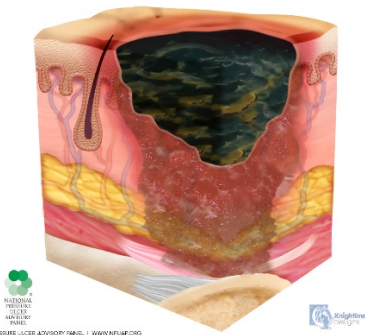
Stage 4 Pressure Injury



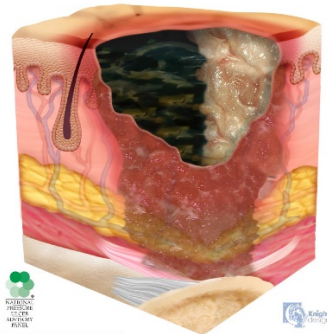
Stage 4 Pressure Injury: Full-thickness skin and tissue loss

Full-thickness skin and tissue loss with exposed or directly palpable fascia, muscle, tendon, ligament, cartilage or bone in the ulcer. Slough and/or eschar may be visible. Epibole (rolled edges), undermining and/or tunneling often occur. Depth varies by anatomical location. If slough or eschar obscures the extent of tissue loss this is an Unstageable Pressure Injury.

Unstageable Pressure Injury - Dark Eschar



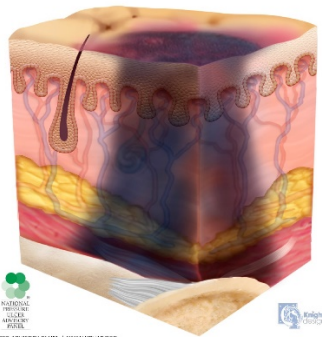
Unstageable Pressure Injury - Slough and Eschar



Unstageable Pressure Injury: Obscured full-thickness skin and tissue loss

Full-thickness skin and tissue loss in which the extent of tissue damage within the ulcer cannot be confirmed because it is obscured by slough or eschar. If slough or eschar is removed, a Stage 3 or Stage 4 pressure injury will be revealed. Stable eschar (i.e. dry, adherent, intact without erythema or fluctuance) on the heel or ischemic limb should not be softened or removed.

Deep Tissue Pressure Injury



Deep Tissue Pressure Injury: Persistent non-blanchable deep red, maroon or purple discoloration

Intact or non-intact skin with localized area of persistent non-blanchable deep red, maroon, purple discoloration or epidermal separation revealing a dark wound bed or blood filled blister. Pain and temperature change often precede skin color changes. Discoloration may appear differently in darkly pigmented skin. This injury results from intense and/or prolonged pressure and shear forces at the bone-muscle interface. The wound may evolve rapidly to reveal the actual extent of tissue injury, or may resolve without tissue loss. If necrotic tissue, subcutaneous tissue, granulation tissue, fascia, muscle or other underlying structures are visible, this indicates a full thickness pressure injury (Unstageable, Stage 3 or Stage 4). Do not use DTPI to describe vascular, traumatic, neuropathic, or dermatologic conditions.

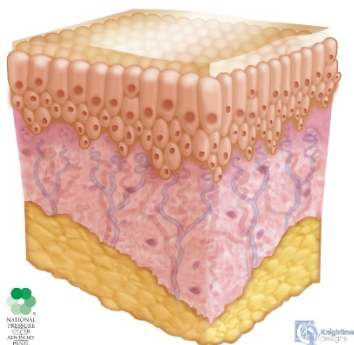
Additional pressure injury definitions.

Medical Device Related Pressure Injury:

This describes an etiology.

Medical device related pressure injuries result from the use of devices designed and applied for diagnostic or therapeutic purposes. The resultant pressure injury generally conforms to the pattern or shape of the device. The injury should be staged using the staging system.

Mucous Membrane



Mucosal Membrane Pressure Injury: Mucosal membrane pressure injury is found on mucous membranes with a history of a medical device in use at the location of the injury. Due to the anatomy of the tissue these ulcers cannot be staged.

- **Item Set Continued**

- **(M1307) The Oldest Stage 2 Pressure Ulcer that is present at discharge.**
(Excludes healed Stage 2 pressure ulcers.)
- **(M1311) Current Number of Unhealed Pressure Ulcers/Injuries at Each Stage.**
- **(M1322) Current Number of Stage 1 Pressure Injuries.**
- **(M1324) Stage of Most Problematic Unhealed Pressure Ulcer/Injury that is Stageable.** (Excludes pressure ulcer/injury that cannot be staged due to a non-removable dressing/device, coverage of wound bed by slough and/or eschar, or deep tissue injury.)
- **(M1330) Does this patient have a Stasis Ulcer?**
- **(M1332) Current Number of Stasis Ulcer(s) that are Observable.**
- **(M1334) Status of Most Problematic Stasis Ulcer that is Observable.**
 - 1 **Fully granulating** - Wound bed filled with granulation tissue to the level of the surrounding skin; and – no dead space; and – no avascular tissue (eschar and/or slough); and – no signs or symptoms of infection; and – wound edges are open.
 - 2 **Early/partial granulation** – Wound bed covered with $\geq 25\%$ of granulation tissue; and – wound bed covered with $< 25\%$ of avascular tissue (eschar and/or slough); and – no signs or symptoms of infection; and – wound edges are open.
 - 3 **Not healing** – Wound with $\geq 25\%$ avascular tissue (eschar and/or slough); or – signs/symptoms of infection; or – clean but nongranulating wound bed; or – closed/hyperkeratotic wound edges; or – persistent failure to improve despite appropriate and comprehensive wound management.
- **(M1340) Does this patient have a Surgical Wound?**
- **(M1342) Status of Most Problematic Surgical Wound that is Observable:**
 - 0 **Newly epithelialized** – Wound bed completely covered with new epithelium; and – no exudate; and – no avascular tissue (eschar and/or slough); and – no signs or symptoms of infection.
 - 1 **Fully granulating** – Wound bed filled with granulation tissue to the level of the surrounding skin; and – no dead space; and – no avascular tissue (eschar and/or slough); and – no signs or symptoms of infection; and – wound edges are open.
 - 2 **Early/partial granulation** – Wound bed is covered with $\geq 25\%$ of granulation tissue; and – wound bed is covered with $< 25\%$ of avascular tissue (eschar and/or slough); and – no signs or symptoms of infection; and – wound edges are open.
 - 3 **Not healing** – Wound with $\geq 25\%$ avascular tissue (eschar and/or slough); or signs/symptoms of infection; or – clean but nongranulating wound bed; or – closed/hyperkeratotic wound edges; or – persistent failure to improve despite appropriate and comprehensive wound management.

Glossary

- Avascular.** Lacking in blood supply; synonyms are dead, devitalized, necrotic, and nonviable. Specific types of avascular tissue include slough and eschar.
- Clean Wound.** Wound is free of avascular tissue, purulent drainage, foreign material, or debris.
- Closed Wound Edges.** Edges of the top layers of epidermis have rolled down to cover the lower edge of the epidermis, including the basement membrane, so that epithelial cells cannot migrate from the wound edges. This condition is also known as epibole. It presents clinically as a sealed edge of mature epithelium, which may be hardened, thickened, and discolored (e.g., yellowish, gray, or white).
- Dead Space.** A defect or cavity in a wound.
- Epibole.** See closed wound edges.
- Epidermis.** The outermost layer of skin.
- Epithelialized.** Regeneration of the epidermis across a wound surface.
- Eschar.** Black or brown avascular tissue; tissue can be loose or firmly adherent, hard, soft or soggy.
- Full Thickness.** Tissue damage involving a total loss of the epidermis and dermis that extends into the subcutaneous tissue and may expose muscle, bone, or underlying structures.
- Granulation Tissue.** The pink/red, moist tissue comprised of new blood vessels, connective tissue, fibroblasts, and inflammatory cells, which fills an open wound when it starts to heal; and typically appears deep pink or red with an irregular, “berry-like” surface.
- Healing.** A dynamic process involving synthesis of new tissue for repair of skin and soft tissue defects.
- Hyperkeratotic.** Hard, white/gray tissue surrounding the wound resulting from thickening/hypertrophy of the horny layer (stratum corneum) of the epidermis (Farlex Partner Medical Dictionary, 2012).
- Infection.** The presence of bacteria or other microorganisms in sufficient quantity to damage tissue or impair healing. Infection has been defined as a bacterial bioburden of equal to or greater than 10⁵ colony forming units per gram of tissue or cm² swab, and/or the presence of Beta-hemolytic Streptococci (NPUAP et al., 2014; Weir & Schultz, 2016). Typical signs and symptoms of infection include purulent exudate, odor, erythema, warmth, tenderness, edema, pain, fever, and an elevated white blood cell count. However, clinical signs of infection may not be present, especially in the immunocompromised patient or the patient with poor perfusion.
- Necrotic Tissue.** See avascular.
- Newly epithelialized.** The process of regeneration of the epidermis across a wound surface or regeneration of the epidermis across a wound surface.
- Nonepithelialized.** Absence of the regeneration of the epidermis across a wound surface.
- Nongranulating.** Absence of granulation tissue; the wound surface appears smooth as opposed to granular. For example, in a wound that is clean but nongranulating, the wound surface appears smooth and red as opposed to “berry-like”.
- Partial Thickness.** Tissue damage confined to the skin layers; damage does not penetrate below the dermis and may be limited to the epidermal layers only.
- Sinus Tract.** A course or path of tissue destruction occurring in any direction from the surface or edge of the wound (also called “tunneling”), which results in dead space with a potential for abscess formation. It can be distinguished from undermining by the fact that a sinus tract

involves a small portion of the wound edge; whereas, undermining involves a significant portion of the wound edge.

Slough. Soft, moist, avascular tissue; may be white, yellow, tan, or green; and may be loose or firmly adherent.

Stage 4 Structures. Anatomical structures, any of which when visible in a full-thickness pressure ulcer, indicate the wound is reportable as a Stage 4 pressure ulcer. Stage 4 structures include bone, muscle, tendon, and joint capsule.

Tunneling. See sinus tract.

Undermining. An area of tissue destruction extending under intact skin along the periphery of a wound that is commonly seen in shear injuries. It can be distinguished from a sinus tract by the fact that undermining involves a significant portion of the wound edge; whereas, a sinus tract involves only a small portion of the wound edge.

Unhealed. Absence of the skin's original integrity.

References

- Centers for Medicare & Medicaid Services. (2018a). *OASIS User Manuals: draft-OASIS-D Guidance Manual*. Retrieved November 17, 2018, from <https://www.cms.gov>
- Centers for Medicare & Medicaid Services. (2018b). *OASIS-D guidance manual-effective 1-1-2019*. Appendix G-4, G-5. Retrieved November 17, 2018, <https://www.cms.gov/Medicare/Quality-Initiatives-Patient-Assessment-Instruments/HomeHealthQualityInits/Downloads/draft-OASIS-D-Guidance-Manual-7-2-2018.pdf>
- Centers for Medicare & Medicaid Services. (2018c). *OASIS-D guidance manual-effective 1-1-2019*. Chapter 3: F-1. Retrieved November 17, 2018, <https://www.cms.gov/Medicare/Quality-Initiatives-Patient-Assessment-Instruments/HomeHealthQualityInits/Downloads/draft-OASIS-D-Guidance-Manual-7-2-2018.pdf>
- Centers for Medicare & Medicaid Services. (2018d). *OASIS-D guidance manual-effective 1-1-2019. Chapter 3: Section F- Integumentary*. Retrieved November 17, 2018, <https://www.cms.gov/Medicare/Quality-Initiatives-Patient-Assessment-Instruments/HomeHealthQualityInits/Downloads/draft-OASIS-D-Guidance-Manual-7-2-2018.pdf>
- Farlex Partner Medical Dictionary. (2012). *Hyperkeratotic*. Retrieved April 3, 2016, from <http://medicaldictionary.thefreedictionary.com/hyperkeratotic>
- National Pressure Ulcer Advisory Panel, European Pressure Ulcer Advisory Panel, & Pan Pacific Pressure Injury Alliance. (2014). *Prevention and treatment of pressure ulcers: Quick reference guide*. Emily Haesler (Ed.). Osborne Park, Western Australia: Cambridge Media. Retrieved May 5, 2016, from <http://www.npuap.org/wp-content/uploads/2014/08/Quick-Reference-Guide-DIGITAL-NPUAPEPUAP-PPPIA-Jan2016.pdf>
- National Pressure Ulcer Advisory Panel. (2016). *NPUAP pressure injury stages*. Retrieved December 12, 2018, from <http://www.npuap.org/resources/educational-and-clinical-resources/npuap-pressure-injury-stages>
- Weir, D., & Schultz, G. (2016). Assessment and management of wound-related infections. In D. B. Doughty & L. L. McNichol (Eds.), *Wound, Ostomy and Continence Nurses Society core curriculum: Wound management* (pp.156–180). Philadelphia, PA: Wolters Kluwer.
- Wound, Ostomy and Continence Nurses Society. (2016). *Wound, Ostomy and Continence Nurses Society's guidance on OASIS-C2 integumentary items: Best practice for clinicians*. Mt. Laurel, NJ: Author.

Acknowledgment about Content Validation

This document was reviewed in the consensus-building process of the Wound, Ostomy and Continence Nurses Society known as Content Validation.